

19 Ogilvie's syndrome

Michael D Saunders, Michael B Kimmey

Introduction

Acute colonic pseudo-obstruction (ACPO), also referred to as Ogilvie's syndrome,¹ is a clinical condition with symptoms, signs and radiographic appearance of acute large bowel obstruction without a mechanical cause. ACPO occurs most often in hospitalized or institutionalized patients with serious underlying medical and surgical conditions. ACPO is an important cause of morbidity and mortality. The mortality rate is estimated at 40% when ischemia or perforation occurs.² Early detection and prompt appropriate management are critical to minimizing morbidity and mortality.

Pathogenesis

The pathogenesis of ACPO is not completely understood but likely results from an alteration in the autonomic regulation of colonic motor function.³ Colonic pseudo-obstruction was first described in 1948 by Sir Heneage

Ogilvie, who reported two patients with chronic colonic dilation associated with malignant infiltration of the celiac plexus.¹ Ogilvie attributed the syndrome to sympathetic deprivation. A better understanding of the autonomic nervous system in the gut has modified this hypothesis. The parasympathetic nervous system increases contractility, whereas the sympathetic nerves decrease motility.³ An imbalance in autonomic innervation, produced by a variety of factors, leads to excessive parasympathetic suppression or sympathetic stimulation. The result is colonic atony and pseudo-obstruction.

Multiple predisposing factors or conditions have been associated with ACPO (Table 19.1). In a large retrospective series of 400 patients, the most common predisposing conditions were non-operative trauma (11.3%), infections (10%), and cardiac disease (10%).² Cesarean section and hip surgery were the most common surgical procedures, with the onset of the syndrome occurring post-operatively at an average of 4-5 days. In another retrospective analysis of 48 patients, the spine or retroperitoneum had been traumatized or manipulated

Table 19.1 Predisposing conditions associated with acute colonic pseudo-obstruction – an analysis of 400 cases^a

Condition	No. of patients	Proportion (%)
Trauma (non-operative)	45	11.3
Infection (pneumonia, sepsis most common)	40	10.0
Cardiac (myocardial infarction, heart failure)	40	10.0
Obstetrics/gynecology	39	9.8
Abdominal/pelvic surgery	37	9.3
Neurologic	37	9.3
Orthopedic surgery	29	7.3
Miscellaneous medical conditions (metabolic, cancer, respiratory failure, renal failure)	128	32
Miscellaneous surgical conditions (urologic, thoracic, neurosurgery)	47	11.8

^aAssociated conditions in approximately 400 patients, reported by Vanek and Al-Salti.² Some patients had more than one associated condition.

in 52%.⁴ Over half the patients were receiving narcotics, and electrolyte abnormalities were present in approximately two-thirds. Thus, multiple metabolic, pharmacologic, or traumatic factors appear to alter the autonomic regulation of colonic function resulting in pseudo-obstruction.

Clinical features

The clinical features of ACPO include abdominal distension, abdominal pain (80%), and nausea and/or vomiting (60%).² Passage of flatus or stool is reported in up to 40% of patients. There is no significant difference in symptoms of patients with ischemic or perforated bowel, except for a higher incidence of fever.² On examination, the abdomen is tympanic and bowel sounds are typically present. Fever, marked abdominal tenderness and leukocytosis are more common in patients with ischemia or perforation but also occur in those who have not developed these complications.²

The diagnosis of ACPO is confirmed by plain abdominal radiographs, which show varying degrees of colonic dilatation (Figure 19.1). Air fluid levels and dilatation can also be seen in the small bowel. Typically, the right colon and cecum show the most marked distension, and cut-offs at the splenic flexure are common. This distribution of colonic dilation may be caused by the different origins of the proximal and distal parasympathetic nerve supply to the colon.³ A water soluble contrast enema should be obtained to exclude mechanical obstruction if gas and distension are not present throughout all colonic segments including the rectum and sigmoid colon.

Keys to management of ACPO include (i) early recognition and diagnosis, (ii) evaluation to exclude mechanical obstruction or other causes of pseudo-obstruction (such as *Clostridium difficile* colitis⁵), (iii) assessment for signs of ischemia or perforation which would warrant urgent surgical intervention, and (iv) initiation of appropriate treatment measures.

Management

Treatment options for ACPO include appropriate supportive measures, medical therapy, colonoscopic decompression, and surgery. Despite extensive literature documenting the clinical features of ACPO, there are very few randomized controlled clinical trials on the treatment of this condition, and most evidence for efficacy of treatments comes from uncontrolled studies.

Supportive therapy

Supportive therapy (Box 19.1) should be instituted in all patients as it appears to be successful as the primary treatment in the majority of patients.⁶ B4 Patients are given

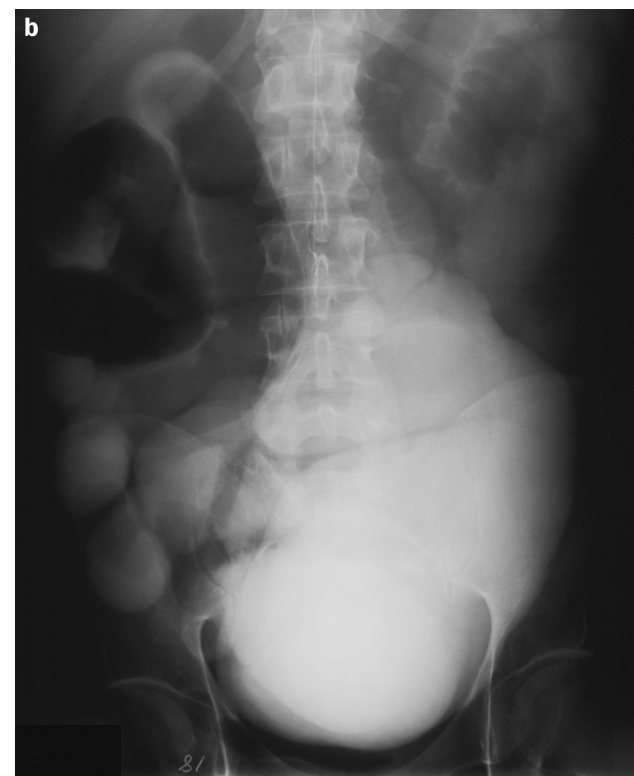
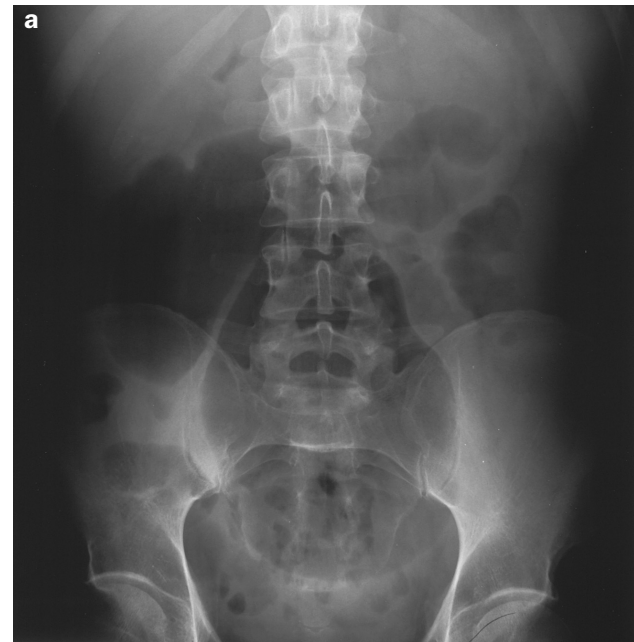


Figure 19.1 Abdominal radiographs of a patient with acute colonic pseudo-obstruction. (a) The plain abdominal film shows marked dilatation, especially of the right colon. In addition, moderate small bowel dilatation is present. (b) A water soluble contrast enema was obtained excluding mechanical obstruction

Box 19.1 Supportive therapy for acute colonic pseudo-obstruction

- Nil per os
- Correct fluid and electrolyte imbalances
- Nasogastric tube suction
- Rectal tube to gravity drainage
- Limit offending medications (especially narcotics)
- Frequent position changes, ambulate if possible

nothing by mouth. Intravenous fluids are administered and electrolyte imbalances are corrected. Nasogastric suction is provided to limit swallowed air from contributing further to colonic distension. A rectal tube should be inserted and attached to gravity drainage. Medications that can adversely affect colonic motility, such as opiates, anti-cholinergics, and calcium channel antagonists are discontinued if possible. Ambulation and mobilization of patients are encouraged. The knee-chest position with hips held high has been advocated as aiding in evacuation of colonic gas.⁷ None of these supportive measures has been studied in a randomized trial. **C5**

The reported success of supportive management is variable with pooled rates from several retrospective series of approximately 85%.^{6,8-12} In these combined series, 111 patients were treated conservatively, of which 95 (86%) had resolution of the pseudo-obstruction. **B4** Sloyer *et al.* reported outcomes of 25 cancer patients with ACPO (mostly non-gastrointestinal malignancies).⁶ The mean cecal diameter was 11.7 cm (range 9–18 cm). Of the 24 patients treated conservatively, 23 (96%) improved by clinical and radiologic criteria with the median time to improvement of 1.6 days (mean 3 days). There were no perforations or ACPO-related deaths. The authors concluded that early endoscopic or surgical decompression is not necessary in patients with ACPO. **B4** In another recent retrospective series of 151 patients reported by Loftus *et al.*, 117 (77%) had spontaneous resolution of ACPO with conservative treatment.¹³ **B4** These studies demonstrate that the initial management of ACPO should be directed towards eliminating or reducing the factors known to contribute to the problem.

Patient outcome

The clinical dilemma facing the clinician caring for a patient with ACPO is whether to treat the patient with conservative measures and close observation versus proceeding with medical or endoscopic decompression of the dilated colon. The outcome of patients with ACPO is determined by multiple factors. The severity of the underlying illness appears to exert the greatest influence on patient outcome. ACPO often afflicts debilitated patients, which explains the significant morbidity and mortality even with successful treatment of the colonic dilatation. Other factors

that appear to influence outcome are increasing age, maximal cecal diameter, delay in decompression and status of the bowel.² The risk of spontaneous colon perforation in ACPO is low but clearly exists. Rex reviewed all available reports in the literature and estimated the risk of spontaneous perforation to be approximately 3%.¹⁴ The mortality rate in ACPO is approximately 40% when ischemia or perforation are present, compared with 15% in patients with viable bowel.² Retrospective analyses of patients with ACPO^{2,12} have attempted to identify clinical factors that predict which patients are more likely to have complications such as ischemia or perforation. The risk of colonic perforation has been reported² to increase with cecal diameter greater than 12 cm and when distension has been present for more than 6 days.¹² In the large series reported by Vanek and Al-Salti, no cases of perforation were seen when the cecal diameter was less than 12 cm.² However, at diameters greater than 12 cm, there was no clear relationship between risk of ischemia or perforation and the size of the cecum. The duration and progression of colonic distension may be more important. Johnson and Rice reported a mean duration of distension of 6 days in patients who perforated compared with 2 days in those who did not.¹² A two-fold increase in mortality occurs when cecal diameter is greater than 14 cm and a five-fold increase when delay in decompression is greater than 7 days.² Thus, the decision to intervene with medical therapy, colonoscopy or surgery is dictated by the patient's clinical status. On the basis of the limited available evidence patients with marked cecal distension (> 10 cm) of significant duration (> 3–4 days) and those not improving after 24–48 hours of supportive therapy are considered to be candidates for further intervention. **B4** In the absence of signs of ischemia or perforation, medical therapy with neostigmine should be considered the initial therapy of choice.

Medical therapy

Neostigmine

The only randomized controlled trial of an intervention for ACPO involves the use of neostigmine.¹⁵ Neostigmine, a reversible acetylcholinesterase inhibitor, indirectly stimulates muscarinic receptors, thereby enhancing colonic motor activity, inducing colonic propulsion and accelerated transit.¹⁶ The rationale for using neostigmine stems from the imbalance in autonomic regulation of colonic function that is proposed to occur in ACPO. Neostigmine was first used for manipulation of the autonomic innervation to the gastrointestinal tract by Neely and Catchpole over 30 years ago in studies on small bowel paralytic ileus.¹⁷ Neostigmine, administered intravenously, has a rapid onset (1–20 minutes) and short duration (1–2 hours) of action.¹⁸ The elimination half-life

Table 19.2 Neostigmine for colonic decompression in patients with acute colonic pseudo-obstruction

Study	No. of patients	Design	Dose	Decompression	Recurrence
Ponec <i>et al.</i> (1999) ¹⁵	21 (neostigmine 11, placebo 10)	RCT; (OL in non-responders)	2.0 mg IV over 3–5 min	Neostigmine 10/11 in RCT; 17/18 total; placebo 0/10	2
Hutchinson and Griffiths (1992) ²⁰	11	OL	2.5 mg IV in 1 min	8/11	0
Stephenson <i>et al.</i> (1995) ²¹	12	OL	2.5 mg IV over 1–3 min	12/12 (2 patients required 2 doses)	1
Turegano-Fuentes <i>et al.</i> (1997) ²²	16	OL	2.5 mg IV over 60 min	12/16	0
Trevisani <i>et al.</i> (2000) ²³	28	OL	2.5 mg IV over 3 min	26/28	0
Paran <i>et al.</i> (2001) ²⁴	11	OL	2.5 mg IV over 60 min	10/11 (2 patients required 2 doses)	0
Abeyta <i>et al.</i> (2001) ²⁵	8	Retrospective	2.0 mg IV	6/8 (2 patients required 2 doses)	0
Loftus <i>et al.</i> (2002) ¹³	18	Retrospective	2.0 mg IV	16/18	5

RCT, randomized controlled trial; OL, open label trial; IV, intravenous

averages 80 minutes, but is more prolonged in patients with renal insufficiency.¹⁹

A randomized double blind placebo-controlled trial evaluated neostigmine in patients with ACPO with a cecal diameter of > 10 cm and no response to 24 hours of conservative therapy.¹⁵ Exclusion criteria were suspected ischemia or perforation, pregnancy, severe active bronchospasm, cardiac arrhythmias and renal failure. Patients were randomized to receive neostigmine, 2 mg, or saline by intravenous infusion over 3–5 minutes. The primary endpoint was the clinical response to infusion, defined as a prompt reduction in abdominal distension by physical examination. Secondary endpoints included the change in measurements of colonic diameter on radiographs and abdominal girth. Patients not responding within 3 hours to initial infusion were eligible for open label neostigmine. A clinical response was observed in 10 of 11 patients (91%) randomized to receive neostigmine compared to 0 of 10 receiving placebo.

Ald The median time to response was 4 minutes. Median reduction in cecal diameter (5 cm ν 2 cm) and abdominal girth (7 cm ν 1 cm) were significantly reduced in neostigmine-treated patients. Open label neostigmine was administered to eight patients who failed to respond to the initial infusion (seven placebo, one neostigmine), and all had prompt decompression. Of the 18 patients who received neostigmine, either initially or during open label treatment, 17 (94%) had a clinical response. The recurrence rate of colonic distension after neostigmine decompression was low (11%). The most common adverse effects observed with neostigmine were mild abdominal cramping and excessive salivation. Symptomatic bradycardia requiring atropine occurred in two of 19 patients.

There are also several uncontrolled observational studies supporting the use of neostigmine in this condition.^{13,20–25} Collectively, rapid decompression of colonic distension was observed in 88% of patients with a recurrence rate of 7% (Table 19.2). **B4** The cost of neostigmine is minimal, with a 2 mg ampoule for parenteral use costing only US\$3.¹⁵ The cost to the patient after storage and handling fees are included is approximately US\$15.

Although neostigmine was associated with a favorable safety profile in the reported clinical trials, caution should be used when administering the medication. Neostigmine should be administered with the patient kept supine in bed with continuous electrocardiographic monitoring, physician assessment and measurement of vital signs for 15–30 minutes following administration.¹⁵ Contraindications to its use include mechanical bowel obstruction, presence of ischemia or perforation, pregnancy, uncontrolled cardiac arrhythmias, severe active bronchospasm, and renal insufficiency.

Thus, neostigmine appears to be an effective, safe and inexpensive method of colonic decompression in ACPO. The published data support its use as the initial therapy of choice for patients not responding to conservative therapy if there are no contraindications to its use. **Ald, B4** In patients with only a partial response or recurrence after an initial infusion, a repeated dose is reasonable and often successful. If the patient fails to respond after two doses, proceeding with colonoscopic decompression is advised.

Other medications

There are only anecdotal reports using other prokinetic agents in ACPO, and their use for the treatment of this

Table 19.3 Observational studies of colonoscopic decompression in acute colonic pseudo-obstruction

Study	No. of patients	Successful initial decompression (%)	Overall colonoscopic success (%)	Complications
Nivatvongs <i>et al.</i> (1982) ³¹	22	68	73	< 1% (no perforations)
Strodel <i>et al.</i> (1983) ³²	44	61	73	2% (1 perforation)
Bode <i>et al.</i> (1984) ³³	22	68	77	4.5% (1 perforation)
Jetmore <i>et al.</i> (1992) ⁴	45	84	36	< 1% (no perforations)
Geller <i>et al.</i> (1996) ³⁴	41	95	18	2% (2 perforations)

condition cannot be recommended. Erythromycin, a motilin receptor agonist, has been reported to be successful in treating patients in a few case reports.^{26,27} Armstrong *et al.* reported decompression in two patients with ACPO with oral erythromycin (500 mg four times daily) for 10 days.²⁶ In another report, one patient had resolution of ACPO after 3 days of intravenous erythromycin therapy.²⁷ Cisapride, a partial 5-HT₄-receptor agonist, has also been employed with some success in patients with ACPO.²⁸ However, this agent is no longer available for use in the USA and Canada due to class III antiarrhythmic properties. Second generation 5-HT₄ partial receptor agonists, such as tegaserod, may be more active at the colonic level than cisapride.²⁹ **C5** However, data evaluating these agents in ACPO are not available.

Endoscopic decompression

Colonoscopic decompression may be required in patients with persistent, marked colonic dilatation that has failed to respond to supportive therapy and neostigmine or when neostigmine is contraindicated. There is no well-defined standard of care regarding the use of colonoscopy in ACPO.⁷ Colonoscopic decompression appears to be beneficial in ACPO, but it is associated with a greater risk of complications, is not completely effective and can be followed by recurrence.³⁰ **B4** Colonoscopy is done to prevent bowel ischemia and perforation. It should not be done if these complications have already developed.

Colonoscopy in ACPO is a technically difficult procedure and should be carried out by experts. Oral laxatives and bowel preparations should not be administered prior to colonoscopy. Air insufflation should be minimized and the entire colon need not be examined. Prolonged attempts at cecal intubation are not necessary because reaching the hepatic flexure usually appears to be effective. Gas should be aspirated and the viability of the mucosa assessed during slow withdrawal of the endoscope. A tube for decompression should be placed in the right colon with the aid of a guidewire and fluoroscopic guidance. Commercially available, single use, over-the-wire colon decompression tubes are available. The guidewires for these kits are quite flexible (0.035 inches (0.89 mm)) and must be watched under fluoroscopy during

advancement and endoscopic withdrawal to minimize loops from forming and ensure placement into the right colon.

The efficacy of colonoscopic decompression has not been established in randomized trials. Successful colonoscopic decompression has been reported in many retrospective case series, now totaling many hundreds of patients.^{4,31-34}

B4 Table 19.3 summarizes the larger reported series of colonoscopic decompression in ACPO. Rex reviewed the available literature of patients with ACPO treated with colonoscopy.³⁰ Successful initial decompression, determined by a reduction in radiographically measured cecal diameter was observed in 69% of 292 patients. Forty percent of patients treated without decompression tube placement had at least one recurrence, requiring an additional colonoscopy. Thus, an initial decompression colonoscopy without tube placement can be considered to be definitive therapy for less than 50% of patients.³⁰ To improve the therapeutic benefit, decompression tube placement at the time of colonoscopy is strongly recommended. The value of decompression tubes has not been evaluated in controlled trials, but anecdotal evidence suggests that they may lower the recurrence rate. In the series reported by Geller *et al.*, the overall clinical success of colonoscopic decompression was 88%. However, in procedures where a decompression tube was not placed the clinical success was poor (25%).³⁴ Tube placement is not, however, completely effective in preventing recurrences. Decompression colonoscopy has a reported colonic perforation rate of approximately 3%,³⁴ a figure that is much higher than is reported in patients without ACPO.

Surgical therapy

Grade C Surgical management is reserved for patients with signs of colonic ischemia or perforation or for those who fail endoscopic and pharmacologic treatment. Surgical intervention is associated with significant morbidity and mortality, probably related to the severity of the underlying medical conditions in this group of patients. In the large retrospective series reported by Vanek and Al-Salti, 179 patients underwent surgery for ACPO with resulting morbidity and mortality rates of 30% and 6%, respectively.²

B4 The type of surgery depends on the status of the bowel.

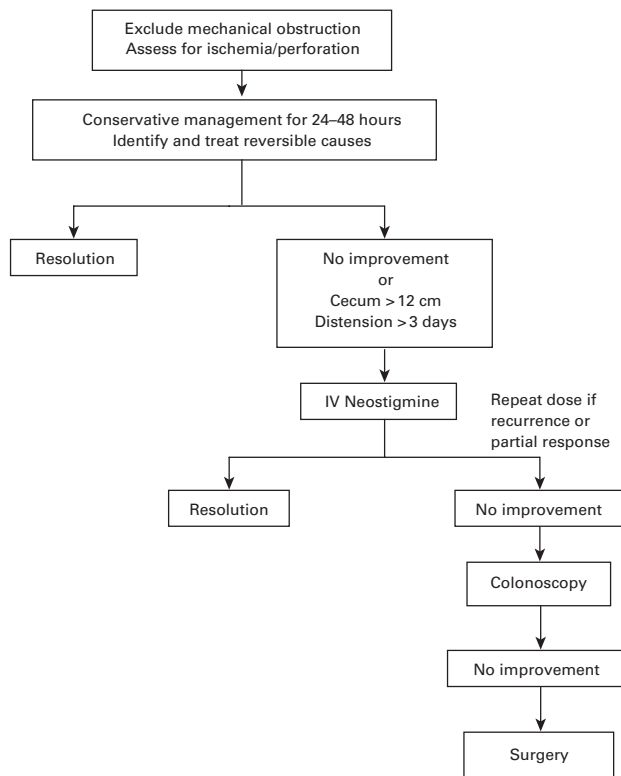


Figure 19.2 Algorithm for suggested management for acute colonic pseudo-obstruction. IV, intravenous

Without perforated or ischemic bowel, cecostomy is the procedure of choice because the success rate is high, morbidity is relatively low and the procedure can be carried out under local anesthesia.² Alternatively, percutaneous cecostomy through a combined endoscopic-radiologic approach can be considered in high surgical risk patients.^{35,36} **C5** In cases of ischemic or perforated bowel, segmental or subtotal colonic resection is indicated, with either exteriorization or primary anastomosis.

Clinical guidelines

An evidence-based guideline for the treatment of ACPO was recently published by the American Society for Gastrointestinal Endoscopy.⁷ The guidelines recommend conservative therapy as the initial preferred management, based on observational studies only. Potentially contributory metabolic, infectious and pharmacologic factors should be identified and corrected. Active intervention is indicated for patients at risk of perforation and/or failing conservative therapy. Neostigmine is effective for the majority of patients. **A4a, B4** Colonic decompression is the initial invasive procedure of choice for patients who fail neostigmine therapy

or for whom this drug is contraindicated. **B4** Surgical decompression should be reserved for patients with peritonitis or perforation and for those who fail endoscopic and medical therapy. **B4** A proposed algorithm for the management of ACPO is detailed in Figure 19.2.

Summary

ACPO is a syndrome of massive dilatation of the colon without mechanical obstruction that results from an imbalance in the autonomic control of the colon. Evaluation involves exclusion of mechanical obstruction and assessing for signs of ischemia or perforation. Appropriate management includes supportive measures and selective use of neostigmine and colonoscopic decompression. Neostigmine is the only therapy for ACPO proved to be efficacious in a randomized controlled trial. Patient outcome is determined by the severity of the predisposing illness, patient age, maximal cecal diameter, duration of colonic distension and viability of the bowel. Of these factors affecting outcome, the latter three are amenable to intervention. Thus, early recognition and management are critical to minimizing morbidity and mortality.

References

- Ogilvie WH. Large intestine colic due to sympathetic deprivation: A new clinical syndrome. *BMJ* 1948;**2**:671-3.
- Vanek VW, Al-Salti M. Acute pseudo-obstruction of the colon (Ogilvie's syndrome). An analysis of 400 cases. *Dis Colon Rectum* 1986;**29**:203-10.
- Dorudi S, Berry AR, Kettlewell MGW. Acute colonic pseudo-obstruction. *Br J Surg* 1992;**79**:99-103.
- Jetmore AB, Timmcke AE, Gathright Jr BJ *et al.* Ogilvie's syndrome: colonoscopic decompression and analysis of predisposing factors. *Dis Colon Rectum* 1992;**35**:1135-42.
- Sheikh RA, Yasmeeen S, Pauly MP *et al.* Pseudomembranous colitis without diarrhea presenting clinically as acute intestinal pseudo-obstruction. *J Gastroenterol* 2001;**36**: 629-32.
- Sloyer AF, Panella VS, Demas BE *et al.* Ogilvie's syndrome. Successful management without colonoscopy. *Dig Dis Sci* 1988;**33**:1391-6.
- Eisen GM, Baron TH, Dominitz JA *et al.* Acute colonic pseudo-obstruction. *Gastrointest Endosc* 2002;**56**:789-92.
- Wandoo H, Mathewson C, Conolly B. Pseudo-obstruction of the colon. *Surg Gynecol Obstet* 1971;**133**:44.
- Meyers MA. Colonic ileus. *Gastrointest Radiol* 1977;**2**: 37-40.
- Bachulis BL, Smith PE. Pseudo-obstruction of the colon. *Am J Surg* 1978;**136**:66-72.
- Baker DA, Morin ME, Tan A *et al.* Colonic ileus: indication for prompt decompression. *JAMA* 1979;**241**:2633-4.

- 12 Johnson CD, Rice RP. The radiographic evaluation of gross cecal distention. *Am J Radiol* 1985;**145**:1211-17.
- 13 Loftus CG, Harewood GC, Baron TH. Assessment of predictors of response to neostigmine for acute colonic pseudo-obstruction. *Am J Gastroenterol* 2002;**97**:3118-22.
- 14 Rex DK. Acute colonic pseudo-obstruction (Ogilvie's syndrome). *Gastroenterology* 1994;**2**:223-8.
- 15 Ponc RJ, Saunders MD, Kimmey MB. Neostigmine for the treatment of acute colonic pseudo-obstruction. *N Engl J Med* 1999;**341**:137-41.
- 16 Law NM, Bharucha AE, Undale AS *et al*. Cholinergic stimulation enhances colonic motor activity, transit, and sensation in humans. *Am J Physiol Gastrointest Liver Physiol* 2001;**281**:G1228-37.
- 17 Neely J, Catchpole B. Ileus: The restoration of alimentary-tract motility by pharmacologic means. *Br J Surg* 1971;**58**:21-8.
- 18 Aquilonius SM, Hartvig P. Clinical pharmacokinetics of cholinesterase inhibitors. *Clin Pharmacokinet* 1986;**11**:236-49.
- 19 Cronnelly R, Stanski DR, Miller RD *et al*. Renal function and the pharmacokinetics of neostigmine in anesthetized man. *Anesthesiology* 1979;**51**:222-6.
- 20 Hutchinson R, Griffiths C. Acute colonic pseudo-obstruction: a pharmacologic approach. *Ann R Coll Surg Engl* 1992;**74**:364-7.
- 21 Stephenson BM, Morgan AR, Salaman JR *et al*. Ogilvie's syndrome: a new approach to an old problem. *Dis Colon Rectum* 1995;**38**:424-7.
- 22 Turegano-Fuentes F, Munoz-Jimenez F, Del Valle-Hernandez E *et al*. Early resolution of Ogilvie's syndrome with intravenous neostigmine. A simple, effective treatment. *Dis Colon Rectum* 1997;**40**:1353-7.
- 23 Trevisani GT, Hyman NH, Church JM. Neostigmine: safe and effective treatment for acute colonic pseudo-obstruction. *Dis Colon Rectum* 2000;**43**:599-603.
- 24 Paran H, Silverberg D, Mayo A *et al*. Treatment of acute colonic pseudo-obstruction with neostigmine. *J Am Coll Surg* 2000;**190**:315-18.
- 25 Abeyta BJ, Albrecht RM, Schermer CR. Retrospective study of neostigmine for the treatment of acute colonic pseudo-obstruction. *Am Surg* 2001;**67**:265-8.
- 26 Armstrong DN, Ballantyne GH, Modlin IM. Erythromycin for reflex ileus in Ogilvie's syndrome. *Lancet* 1991;**337**:378.
- 27 Bonacini M, Smith OJ, Pritchard T. Erythromycin as therapy for acute colonic pseudo-obstruction (Ogilvie's syndrome). *J Clin Gastroenterol* 1991;**13**:475-6.
- 28 MacColl C, MacCannell KL, Baylis B *et al*. Treatment of acute colonic pseudo-obstruction (Ogilvie's syndrome) with cisapride. *Gastroenterology* 1990;**98**:773-6.
- 29 Camilleri M. Review article: tegaserod. *Aliment Pharmacol Ther* 2001;**15**:277-289.
- 30 Rex DK. Colonoscopy and acute colonic pseudo-obstruction. *Gastrointest Endosc Clin North Am* 1997;**7**:499-508.
- 31 Nivatvongs S, Vermeulen FD, Fang DT. Colonoscopic decompression of acute pseudo-obstruction of the colon. *Ann Surg* 1982;**196**:598-600.
- 32 Strodel WE, Nostrant TT, Eckhauser FE *et al*. Therapeutic and diagnostic colonoscopy in non-obstructive colonic dilatation. *Ann Surg* 1983;**19**:416-21.
- 33 Bode WE, Beart RW, Spencer RJ *et al*. Colonoscopic decompression for acute pseudo-obstruction of the colon (Ogilvie's syndrome): report of 22 cases and review of the literature. *Am J Surg* 1984;**147**:243-5.
- 34 Geller A, Petersen BT, Gostout CJ. Endoscopic decompression for acute colonic pseudo-obstruction. *Gastrointest Endosc* 1996;**44**:144-50.
- 35 vanSonnenberg E, Varney RR, Casola G *et al*. Percutaneous cecostomy for Ogilvie's syndrome: laboratory observations and clinical experience. *Radiology* 1990;**175**:679-82.
- 36 Chevallier P, Marcy PY, Francois E *et al*. Controlled transperitoneal percutaneous cecostomy as a therapeutic alternative to the endoscopic decompression for Ogilvie's syndrome. *Am J Gastroenterol* 2002;**97**:471-4.

